



Molecular Identification and Isolation of Avian Poxviruses from Different Bird Species in Iran

Nava Eram¹, Seyed Mostafa Peighambari¹, Seyed Ahmad Madani^{2*}, Abbas Barin¹

1. Department of Avian Diseases, Faculty of Veterinary Medicine, University of Tehran, Tehran, Iran.
2. Department of Animal and Poultry Health and Nutrition, Faculty of Veterinary Medicine, University of Tehran, Tehran, Iran.

How to cite this article: Nava Eram, Seyed Mostafa Peighambari, Seyed Ahmad Madani, Abbas Barin. Molecular Identification and Isolation of Avian Poxviruses from Different Bird Species in Iran. *Archives of Razi Institute*. 2025;80(2):417-423. DOI: 10.32592/ARI.2025.80.2.417



Copyright © 2023 by



Razi Vaccine & Serum Research Institute

Article Info:

Received: 3 September 2024

Accepted: 27 November 2024

Published: 30 April 2025

Corresponding Author's E-Mail:
madani@ut.ac.ir

ABSTRACT

Avian pox, a prevalent viral disease among domestic and wild birds, is caused by different species of avipoxviruses belonging to the family Poxviridae. Different avipoxviruses demonstrated a certain degree of host specificity. In the present study, a total of 105 tissue samples were collected from various avian species that exhibited cutaneous or mucosal proliferative and/or necrotic lesions, which bore a resemblance to pox lesions. The molecular detection of poxviruses was accomplished through the implementation of a polymerase chain reaction (PCR) assay that targeted a highly conserved 4b gene. The samples that were positive for the Polymerase Chain Reaction (PCR) were also used for the isolation of the virus by means of chorioallantoic membrane (CAM) inoculation of embryonated chicken eggs. A pox-like lesion was observed in five avian species, and avipoxvirus was subsequently detected in 19 samples of backyard chickens (42.2%), 24 turkey samples (70.5%), a flock of commercial layer chickens, a flock of commercial breeder turkeys, four canaries (23.5%), two pigeons, and two common mynahs (*Acridotheres tristis*). The propagation of all viruses was conducted on chicken embryo cells (CAM), and the formation of pocks was evident, with the exception of two isolates derived from backyard chickens. A thorough investigation into the genetic relationships among various poxviruses has been conducted through the analysis of partial sequencing of the 4b gene. The study's findings have revealed a notable similarity among poxviruses derived from chickens and turkeys, which have been classified as subclade A1. The present study identified a single instance of pigeon pox in subclade A2. A close proximity of all passerine isolates, including three canarypox viruses and two novel mynahpox viruses from common mynah, was observed in subclade B2. Notwithstanding the long-standing tradition of vaccination, avian pox has been identified in two commercial flocks in disparate provinces, encompassing a layer and a turkey breeder. The present study yielded results indicating the presence of at least three distinct clades of avipoxviruses, which have been identified as the causative agents of avian pox in Galliformes, Columbiformes, and Passeriformes within the Iranian avian population. To the best of the authors' knowledge, this is the inaugural report of molecular typing of mynahpox viruses in Iran.

Keywords: Canarypox, Fowlpox, Mynahpox, Pigeonpox, Iran.

1. Introduction

The genus Avipoxvirus, classified within the subfamily Chordopoxvirinae, encompasses seven distinct species, namely: Fowlpox virus (FWPV), Turkeypox virus (TKPV), Pigeonpox virus (PGPV), Canarypox virus (CNPV), Quailpox virus, Flamingopox virus, and Penguinpox virus (1). Avian pox is a contagious disease manifesting in two forms: cutaneous and/or diphtheritic. It is characterized by proliferative necrotic lesions in birds. The cutaneous form manifests in areas of the skin devoid of feathers, including the periocular, beak, nasal, pedal, and cloacal regions. The diphtheritic form of the disease manifested with necrotic lesions in the mucosal membranes of the oropharyngeal cavity or respiratory tract. The presence of fowl pox in commercial poultry populations has been demonstrated to result in substantial economic losses, primarily attributable to a decline in egg production, a reduction in growth rates, and an escalation in mortality (2). The diagnosis of avian pox is made on the basis of clinical signs, histopathological examinations, serologic methods, virus isolation, and molecular tests (2, 3). The DNA sequences of the 4b gene, which codes for a virion core protein, have frequently been utilized for the purpose of conducting phylogenetic analyses of these viruses (3, 4). Phylogenetic analysis suggests the classification of avipoxviruses into three major clades (A, B, and C). Clade A is subdivided into seven subclades (A1-A7), which encompass the viruses responsible for fowlpox, pigeonpox, and turkeypox (4). Poxviruses from Passeriformes are classified within Clade B, which further subdivided into three distinct subclades (B1-B3). In contrast, clade C viruses are exclusively found in Psittaciformes (5). In the present study, biopsy and necropsy tissue samples were collected from different avian species with mucosal or cutaneous lesions resembling pox. A polymerase chain reaction (PCR) was employed for the molecular detection of poxviruses in the samples. In addition, an attempt was made to isolate avipoxviruses using embryonated chicken eggs. A partial DNA sequencing procedure was conducted on a conserved gene that encodes virion core protein 4b. This procedure was performed for conducting a phylogenetic analysis.

2. Materials and Methods

2.1. Clinical Samples

Tissue specimens from live birds with proliferative and necrotic lesions resembling pox were collected either by skin scratching or by peeling off superficial scabs. Swab samples were collected from mucosal diphtheric lesions when present. Additionally, pooled tissue samples were collected from deceased birds during necropsies, including the liver, lung, spleen, and affected skin or mucosa with characteristic necro-proliferative lesions. In this study, samples from each individual case were minced at a 1:20 ratio in phosphate-buffered saline (PBS) containing penicillin (50 IU/ml), streptomycin (500 µg/ml), and nystatin (100,000 units/ml). Subsequent to a low-speed

centrifugation process at $1000 \times g$ for a duration of 5 minutes, the resultant filtrate was subjected to filtration through a 450 nm filter. Subsequently, one-half of each sample was utilized for DNA extraction. The remaining half of the sample was stored at -20°C for subsequent virus isolation.

2.2. Molecular Detection

The extraction of deoxyribonucleic acid (DNA) was conducted using a commercially available kit (MBST, Tehran, Iran). The molecular diagnosis was conducted using a polymerase chain reaction (PCR) approach, employing a pair of primers that targeted the conserved core protein 4b gene of avipoxviruses, as previously delineated (6). The PCR reaction was composed of the following components: 1.5 units of Taq DNA polymerase (Sinaclon, Iran), 1.5 mM MgCl_2 , 200 µM of each deoxynucleoside triphosphate, 6 pmol of each primer, 60 ng of DNA extracted from the sample, and nuclease-free water up to 25 µL. The amplification process was executed subsequent to an initial denaturation phase at 94°C for two minutes, followed by 35 cycles of one-minute denaturation at 94°C , one-minute annealing at 60°C , and one-minute elongation at 72°C . The final extension step was conducted at a temperature of 72°C for a duration of two minutes (3). Five microliters of the PCR products were then subjected to agarose gel (1.2%) electrophoresis. The live fowl pox vaccine (Razi Vaccine and Serum Research Institute, Iran) was utilized as the positive control. The purification of PCR products was accomplished through the utilization of the AccuPrep® DNA Gel Purification Kit (Bioneer, South Korea).

2.3. Virus Isolation

Samples that were positive for the presence of the polymerase chain reaction (PCR) were inoculated onto the chorioallantoic membranes (CAM) of 9-day-old chicken embryos from a commercial line. A volume of 200 microliters from each sample was inoculated into three embryonated eggs. Inoculated embryos were subjected to an incubation period of seven days at 37°C , after which they were stored in a refrigerated environment. The CAM thickness and the presence of characteristic pocks were examined. Subsequent passages were not performed. Consequently, a polymerase chain reaction (PCR) test was performed on all inoculated CAMs.

2.4. Phylogenetic Analysis

A total of sixteen positive samples and the vaccine strain were subjected to sequencing, as indicated in Table 1. Following the implementation of edits using Bioedit (version 7.2.5) and the exclusion of primer regions, the sequences (578 bp) were aligned with avipoxvirus sequences obtained from GenBank. The genetic relationships and phylogenetic grouping of different strains were investigated using the neighbor-joining method with the Jukes and Cantor model (7, 8). Pairwise genetic and amino acid distances of those strains displaying greater variability in the phylogenetic tree were calculated by MEGA version 7 (9) (Table 1). Avipoxviruses that were

Table 1. Avipoxviruses which were molecularly detected using a conventional PCR targeted 4b gene and subsequently were subjected to partial DNA sequencing.

Laboratory Code	Avian host	Date of detection	Region of origin	Accession Numbers
FPVIR2	Commercial layer (<i>Gallus gallus</i>)	Feb 2017	Tehran	MG787212
FPVIR3	Rural Chicken (<i>Gallus gallus</i>)	August 2014	Mazandaran	MG787213
FPVIR4	Rural Chicken (<i>Gallus gallus</i>)	August 2014	Mazandaran	MG787214
FPVIR5	Rural Chicken (<i>Gallus gallus</i>)	Sep 2014	Mazandaran	MG787215
FPVIR6	Rural Chicken (<i>Gallus gallus</i>)	Sep 2014	Mazandaran	MG787216
FPVIR7	Rural Chicken (<i>Gallus gallus</i>)	Sep 2014	Mazandaran	MG787217
TurPVIR9	Turkey (<i>Melleagris gallopavo</i>)	Sep 2016	Mazandaran	MG787219
TurPVIR10	Turkey (<i>Melleagris gallopavo</i>)	Aug 2014	Mazandaran	MG787220
TurPVIR11	Turkey breeder (<i>Melleagris gallopavo</i>)	Nov 2017	Gilan	MG787221
TurPVIR12	Turkey (<i>Melleagris gallopavo</i>)	Aug 2014	Mazandaran	MG787222
TurPVIR13	Turkey (<i>Melleagris gallopavo</i>)	Aug 2014	Mazandaran	MG787223
CanPVIR14	Canary (<i>Serinus canaria</i>)	Oct 2014	Gilan	MG787224
CanPVIR15	Canary (<i>Serinus canaria</i>)	Oct 2014	Tehran	MG787225
PiPVIR18	Pigeon (<i>Columba livia</i>)	Oct 2014	Gilan	MG787227
MynPVIR21	Common Mynah (<i>Acridotheres tristis</i>)	Dec 2014	Tehran	MW864264
MynPVIR22	Common Mynah (<i>Acridotheres tristis</i>)	Jan 2014	Tehran	MW864264
VacFPVIR	Commercial Vaccine	Not applicable	Tehran	MG787229

molecularly detected using a conventional PCR targeted 4b gene and subsequently were subjected to partial DNA sequencing.

3. Results

3.1. Molecular Detection

A total of 105 tissue specimens were collected from cases that were suspected of belonging to five different species. A total of 49 chickens (*Gallus gallus*) were sampled, including 45 backyard chickens from 14 flocks and four commercial layers. In addition, 35 turkeys (*Meleagris gallopavo*) were sampled, including 34 backyard turkeys from 14 flocks and a commercial turkey breeder. The sample also included 17 canaries (*Serinus canaria*) from six flocks, two pigeons (*Columba livia*), and two common mynahs (*Acridotheres tristis*). According to the findings presented in Table 2, 56 samples (53.33%) were found to be positive for avipoxvirus 4b gene DNA.

3.2. Virus Isolation

It is imperative to note that only samples that were positive for PCR were subjected to the process of virus isolation. All inoculated CAMs exhibited moderate thickening and edema. Typical pock was evident in all samples except for two backyard chickens (Table 2). All CAMs exhibited a positive result in the PCR test. Table 2. A series of experiments were conducted on avian samples to detect the avipoxvirus 4b gene using a polymerase chain reaction (PCR). In addition, a process referred to as poxvirus isolation was carried out by inoculating chicken embryo chorioallantoic membrane (CAM) samples. The investigation revealed the presence of various CAM macroscopic lesion and pock forming capabilities.

3.3. Phylogenetic analysis

Sixteen positive samples were subjected to further study through DNA sequencing of 578 bp 4b. The sequences were submitted to Genbank (Table 1). The analysis of the nucleotide sequences revealed a range of 74% to 100% similarity. The present study identified all avian viruses from the chicken and turkey species, including the vaccine strain, within subclade A1. This subclade exhibited a high degree of similarity with previously reported avipox viruses that shared the same hosts. The sole sequenced pigeon virus was identified within subclade A2. According to the phylogenetic classification (4), both canary poxviruses and a virus from a common mynah were located in subclade B2 (Figure 1). It was revealed that the FPVIR2, FPVIR3, FPVIR4, FPVIR5, FPVIR6, and FPVIR7 were 100% identical to each other as well as to TurPVIR9, TurPVIR10, TurPVIR11, TurPVIR12, and TurPVIR13. FPVIR2 was obtained from a commercial layer farm with a history of 56 weeks of operation. The farm had exhibited typical cutaneous and diphtheric pox lesions, as well as mortalities, despite the presence of documented vaccinations against fowlpox at 16 weeks of age. The TurPVIR11 strain was obtained from a 35-week-old commercial turkey breeder flock. This flock had previously received two vaccinations against fowlpox virus at 10 and 16 weeks of age, using a commercially available fowlpox vaccine. The flock exhibited characteristic pox lesions. The other chicken and turkey isolates were obtained from multispecies small rural flocks located in villages of Mazandaran, Iran. These isolates exhibited a high degree of genetic similarity, ranging from 98% to 100%, with other Iranian (KT003288) and German chicken (AY530304) strains, as well as

Table 2. Avian samples subjected to PCR detection of avipoxvirus 4b gene and poxvirus isolation using chicken embryo chorioallantoic membrane (CAM) inoculation. Different CAM macroscopic lesion and pock forming capabilities were also shown.

Host	Number of individual cases	Number of positive PCR result	Virus isolation and CAM lesion	
			Thickening	Pock formation
Rural Chicken (<i>Gallus gallus</i>)	45	19 (42.2%)	19	17
Domestic Turkey (<i>Melleagris gallopavo</i>)	34	24 (70.58%)	24	24
Commercial layer (<i>Gallus gallus</i>)	4	4 (100%)	4	4
Commercial Breeder Turkey (<i>Melleagris gallopavo</i>)	1	1(100%)	1	1
Canary (<i>Serinus canaries</i>)	17	4 (23.5%)	4	4
Piegon (<i>Columba Livia</i>)	2	2 (100%)	2	2
Common Mynah (<i>Acridotheres tristis</i>)	2	2 (100%)	2	2

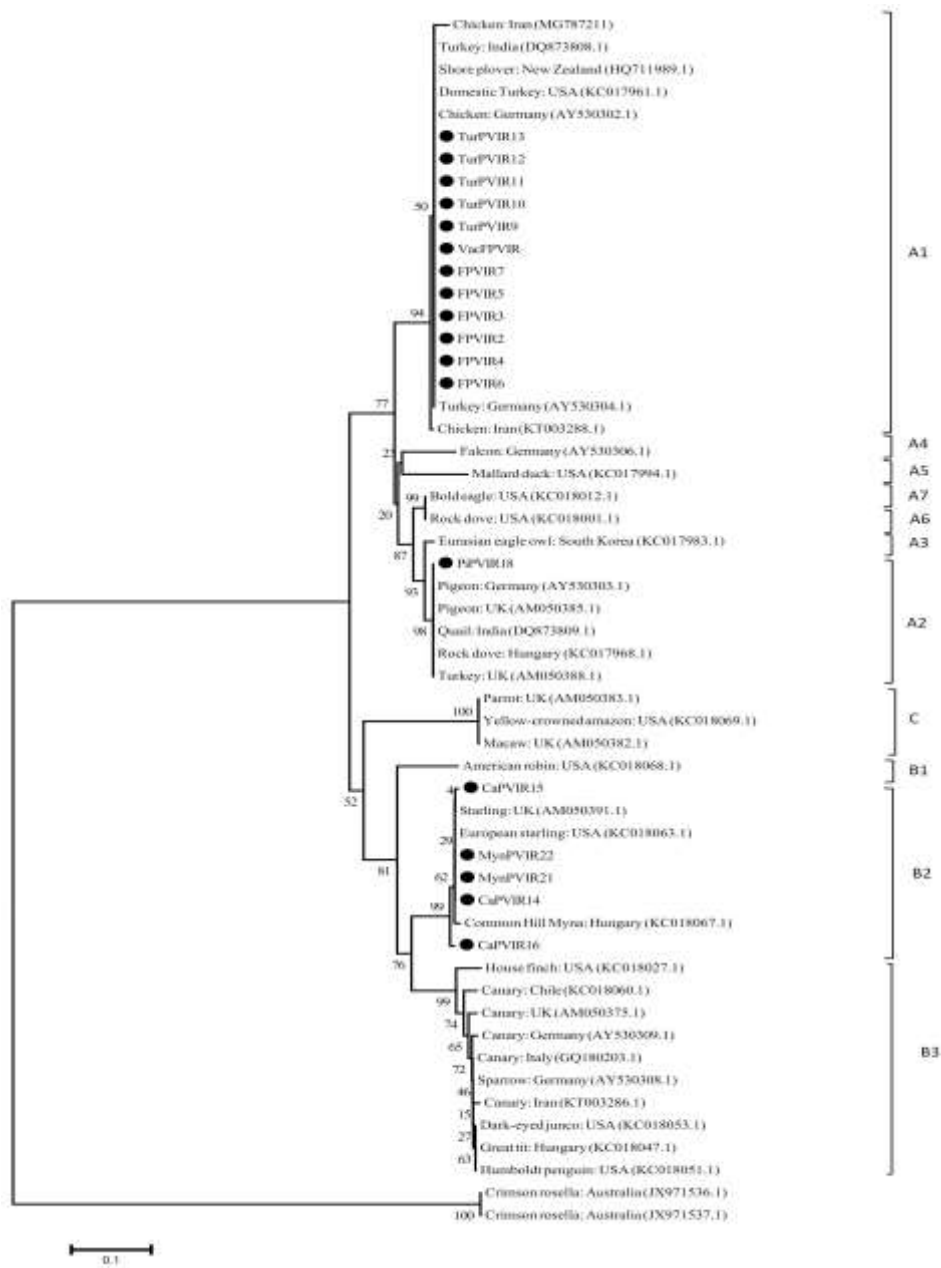


Figure 1. Phylogenetic tree of nucleotide sequence of 4b core protein gene PCR fragment of different avipoxviruses constructed by Neighbor-Joining method with the Jukes and Cantor model. Values at the branches and clusters are bootstrap value and bar indicates distance scale from the roots.

American turkey (KC017961) strains. The pigeon pox virus (PiPVIR18) exhibited 100% similarity to other pigeon pox viruses from Germany (AY530303), the UK (AM050385), and Hungary (KC017968). A close proximity of all four passerine avipoxviruses was observed within subclade B2. Two canarypox viruses, CanPVIR14 and CanPVIR15, exhibited 100% similarity and were classified in the same subclade as an English starling (AM050391), a European starling from the United States (KC018063), and a Hungarian strain from a common hill mynah (*Gracula religiosa*) (KC018067). Two poxviruses from common mynahs (*Acridotheres tristis*), designated as MynPVIR21 and MynPVIR22, exhibited 100% nucleotide identity and were classified within the subclade B2, which encompasses canarypox viruses. To the best of the authors' knowledge, these are the first poxvirus published sequences from common mynahs. The analysis revealed that the isolates in subclade B1 exhibited 75% and 88% similarity with the isolates in subclades A1 and A2, respectively.

4. Discussion

The 4b gene locus has been utilized in phylogenetic studies of avipoxviruses to distinguish major clades A, B, and C, as well as minor subclades (A1-A7 and B1-B3) (5). Pursuant to the findings of the preceding study, subclade A1 comprises viruses derived from Galliformes, encompassing domestic fowl, pheasants, and turkeys. Viruses belonging to the subfamily Columbiformes are classified into two distinct subclades: A2 and A6. Subclades A3 and A5 are predominantly comprised of poxviruses derived from seabirds and Anseriformes, respectively. Avipoxviruses of raptors are predominantly classified into subclades A4 and A7 (5). Eleven poultry isolates from rural chickens, turkeys, commercial layer, and commercial turkey breeders exhibited 100% similarity and were closely grouped in subclade A1. In recent years, studies have been conducted on the prevalence and economic losses due to fowl pox in commercial layer farms and rural poultry in Iran (10, 11). In the present study, all confirmed cases of pox in backyard poultry were observed to occur during the mid-summer to early autumn period. The seasonal pattern of pox infection in birds could be linked to its possible mechanical transmission by arthropods (12, 13). The absence of efficacious biosecurity measures and vaccination protocols can result in an escalation in the prevalence of pox in rural avian populations. The concurrent presence of chickens and turkeys within the same flock, along with poxviruses exhibiting elevated levels of nucleotide identity, has been observed, thereby underscoring the interspecies transmission of fowlpox viruses within these avian species. In the present study, no pox lesions were observed in waterfowls that had close contact with affected chickens and turkeys. The administration of fowlpox vaccination with live vaccines is a standard practice employed to prevent the disease and mitigate its economic losses in commercial poultry, particularly in layers and breeders. Notwithstanding the implementation of vaccination

protocols, a multitude of reports have emerged from various countries (14, 15), including Iran, documenting the occurrence of fowlpox in vaccinated flocks (13, 16, 17). Furthermore, a number of commercial turkey flocks have reported instances of fowlpox, despite the implementation of vaccination protocols (15, 18). In the present study, FPVIR2 was isolated from a commercial layer farm, and TurPVIR11 was isolated from a commercial turkey breeder farm. Both farms had a clear history of vaccination against fowlpox virus. The hypothesis that the integration of avian reticuloendotheliosis virus (REV) into the FWPV genome may be a contributing factor to the observed failure of the vaccine is predicated on the premise that the pathogenesis of FWPV may be amplified by this acquisition of foreign DNA (19, 20). The study's findings indicated that the enhanced virulence or immune evasion of FPVIR2 was not the sole cause of vaccine failure or the improper application of the vaccine, which resulted in the loss of appropriate protection in the affected commercial flocks. The investigation into the presence of integrated DNA in poxviruses in Iran remains an uncharted territory. The taxonomic classification of Clade B is characterized by the presence of poxviruses within the order Passeriformes. Furthermore, two canarypox viruses (CnPVIR14 and CanPVIR15) were found to be in close proximity within subclade B2. The present study contradicts the findings of a previous investigation conducted in Iran. In the aforementioned study, the isolated canarypox viruses were classified as subclade B1 (21). It can be concluded that avipox viruses are capable of infecting canaries in Iran. It is imperative to conduct experimental infection and pathogenicity studies to elucidate the clinical and pathological outcomes of pox infection with different genotypes, as it is a subject that can be investigated in future studies. The sole pigeon isolate in this study was grouped in accordance with the prevailing literature and was found to be in subclade A2, which is consistent with the previously reported pigeonpox viruses. The two novel poxviruses, designated MynPVIR21 and MynPVIR22, were isolated from common mynahs (*Acridotheres tristis*). The two infected mynahs, which were not related to each other, exhibited facial, cutaneous, proliferative, and oral diphtheritic lesions. The precise origins and historical development of the infection remain uncertain. Given the absence of any discernible historical congruence between the two birds in question, the presence of 100% identical 4b sequences in these two isolates could not be attributed to direct transmission between the two individual mynahs. It is noteworthy that these mynahs were captive pets, belonging to different owners. The viruses can be propagated in chicken embryos using CAM inoculation with typical thickening and pock formation. Both were classified as belonging to subclade B2, which is geographically proximate to the canary isolates. As anticipated, the samples were found to be infected with starling pox viruses (AM050391, KC018063) and mynah pox viruses (KC018067) isolated from common hill mynahs (*Gracula*

religiosa) in Hungary. Despite the documented cases of pox lesions in common mynahs, with the virus being isolated and studied in Iran (10, 22), the DNA sequences from this host species remain absent from Genbank. Nonetheless, close relationships with other passerine poxviruses have been documented in previous reports (10). However, a more thorough examination revealed that only 54.9% of the samples were confirmed to be poxvirus infections by PCR. The presence of proliferative or necroderphtheric gross lesions alone may not be sufficient for a diagnosis of avian pox. Lesions of this nature have been known to result from traumatic wounds, scaly mites, irritant chemicals, toxins, nutritional deficiencies, and other infections. These potential etiologies should be ruled out through appropriate diagnostic procedures. Conversely, the negative outcomes may be attributable to sampling errors, which have the potential to yield low levels of virus DNA in the laboratory setting. This, in turn, can result in false negative results in conventional diagnostic PCR (2, 23). In the present study, PCR negative samples were not applied for virus isolation. Avian pox viruses have been isolated from a broad range of avian species, including commercial poultry, wild birds, and companion birds. The present study's findings underscored the significance of avipoxvirus host specificity at the avian order level and the interspecies infectivity of fowl pox viruses. While indistinguishable from one another, two avipoxviruses from common mynahs exhibited a maximum similarity of 94% with canary pox virus with respect to the 4b gene sequence. Further studies are necessary to elucidate their potential host specificity and pathogenicity.

Acknowledgment

This research was supported by the University of Tehran under Grant number 7508007-6-26.

Authors' Contribution

Study concept and design: SAM, NE, SMP

Data acquisition: NE

Laboratory analysis: NE, AB, SAM

Data analysis and interpretation: NE, SAM

Manuscript preparation: NE, SAM, SMP

Critical revision of the manuscript: SAM

Study supervision: SMP, SAM

Ethics

All procedures have been formally endorsed by the Research Council of the University of Tehran, as documented under the research proposal number 7508007-6-26.

Conflict of Interest

The authors have not reported any potential conflicts of interest.

Data Availability

The data that support the findings of this study are available upon request from the corresponding author.

References

- Siddell SG, Smith DB, Adriaenssens E, Alfenas-Zerbini P, Dutilh BE, Garcia ML, et al. Virus taxonomy and the role of the International Committee on Taxonomy of Viruses (ICTV). *Journal of General Virology*. 2023;104(5):001840.
- Tripathy DN, Reed WM. Pox. *Diseases of poultry*. 2013:333-49.
- Manarolla G, Pisoni G, Sironi G, Rampin T. Molecular biological characterization of avian poxvirus strains isolated from different avian species. *Veterinary microbiology*. 2010;140(1-2):1-8.
- Jarmin S, Manvell R, Gough RE, Laidlaw SM, Skinner MA. Avipoxvirus phylogenetics: identification of a PCR length polymorphism that discriminates between the two major clades. *Journal of General Virology*. 2006;87(8):2191-201.
- Gyuranecz M, Foster JT, Dán Á, Ip HS, Egstad KF, Parker PG, et al. Worldwide phylogenetic relationship of avian poxviruses. *Journal of virology*. 2013;87(9):4938-51.
- Lee LH, Lee KH. Application of the polymerase chain reaction for the diagnosis of fowl poxvirus infection. *Journal of Virological Methods*. 1997;63(1-2):113-9.
- Saitou N, Nei M. The neighbor-joining method: a new method for reconstructing phylogenetic trees. *Molecular biology and evolution*. 1987;4(4):406-25.
- Tamura K, Nei M, Kumar S. Prospects for inferring very large phylogenies by using the neighbor-joining method. *Proceedings of the National Academy of Sciences*. 2004;101(30):11030-5.
- Kumar S, Stecher G, Tamura K. MEGA7: molecular evolutionary genetics analysis version 7.0 for bigger datasets. *Molecular biology and evolution*. 2016;33(7):1870-4.
- Nayeri FB, Madadgar O, Ghalyanchi LA, Ghafari M. Molecular detection and phylogenetic analysis of Avipoxvirus strains isolated from different bird species. 2014.
- Norouzian H, Farjanikish G. Pathological and molecular diagnosis of avian pox in backyard chickens in Khorram Abad. *Veterinary Research & Biological Products*. 2017;30(4):2-10.
- KEY BL, NAYAR JK, FORRESTER DJ. AVIAN POX IN FLORIDA WILD TURKEYS: *Culex nigripalpus* AND *Wyeomyia vanduzeei* AS EXPERIMENTAL VECTORS1. *Journal of Wildlife Diseases*. 1981;17(4):597-9.

13. Eram N, Peighambari SM, Madani SA, Razmyar J, Barin A. Sequence and phylogenetic study of two fowlpox virus isolates obtained from layer chickens and red mite (*Dermanyssus gallinae*) in 2016. 2020.
14. Nakamura K, Waseda K, Yamamoto Y, Yamada M, Nakazawa M, Hata E, et al. Pathology of cutaneous fowlpox with amyloidosis in layer hens inoculated with fowlpox vaccine. *Avian Diseases*. 2006;50(1):152-6.
15. Odoya E, Abegunde A, Agyogbo B, Omatainse S, Gwankat E, Okpara U. Outbreak of turkey pox disease in fowl pox vaccinated poult in Vom Plateau State of Nigeria. *African Journal of Clinical and Experimental Microbiology*. 2006;7(2):136-8.
16. Moayyedean H, Mirmohammad-Sadeghi A, Hasanshahi R. Clinical and histopathological survey of lesions similar to pox skin lesions in three flocks of a large commercial layer farm. *Journal of Applied Poultry Research*. 2008;17(4):556-8.
17. Fallah Mehrabadi M, Ghalyanchilangeroudi A, Charkhkar S, Hosseini H, Zabihpetroudi T, Shayganmehr A, et al. laying Farm: Up to Date Data on a Fowlpox Outbreak in Phylogenetic Analysis in Iran, 2018. *Archives of Razi Institute*. 2020;75(4).
18. Ferreira BC, Ecco R, Couto RM, Coelho HE, Rossi DA, Beletti ME, et al. Outbreak of cutaneous form of avian poxvirus disease in previously pox-vaccinated commercial turkeys. *Pesquisa Veterinária Brasileira*. 2018;38:417-24.
19. Singh P, Kim T-J, Tripathy D. Re-emerging fowlpox: evaluation of isolates from vaccinated flocks. *Avian Pathology*. 2000;29(5):449-55.
20. Singh P, Tripathy DN. Fowlpox virus infection causes a lymphoproliferative response in chickens. *Viral Immunology*. 2003;16(2):223-7.
21. Ghalyanchilangeroudi A, Hosseini H, Morshed R. Molecular characterization and phylogenetic analysis of avian pox virus isolated from pet birds and commercial flocks, in Iran. 2018.
22. Madani S, Eram N, Rezaeifar A, Arabkhazaeli F, editors. Common diseases of common mynah (*Acridotheres tristis*): frequently observed pathologies in referred cases. *Proceedings of the 1st International Conference on Avian Herpetological and Exotic Mammals Medicine*; 2013: VVB Laufersweiler Verlag Gissen.
23. Parker PG, Buckles EL, Farrington H, Petren K, Whiteman NK, Ricklefs RE, et al. 110 years of Avipoxvirus in the Galapagos Islands. *Plos one*. 2011;6(1):e15989.